

# IOTA Risk Assessment Models

## Ovarian tumor analysis with Voluson™



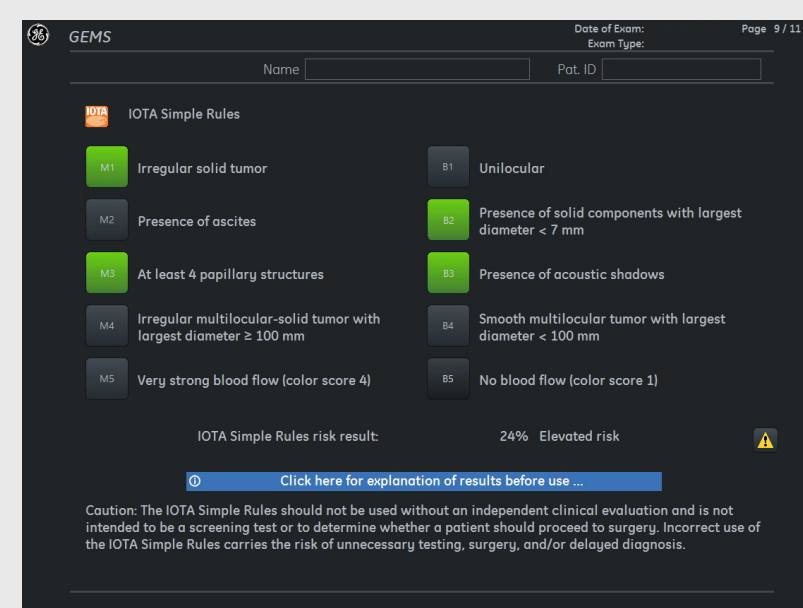
### SIMPLE RULES RISK CALCULATOR

#### Pre-operative classification system for ovarian tumors

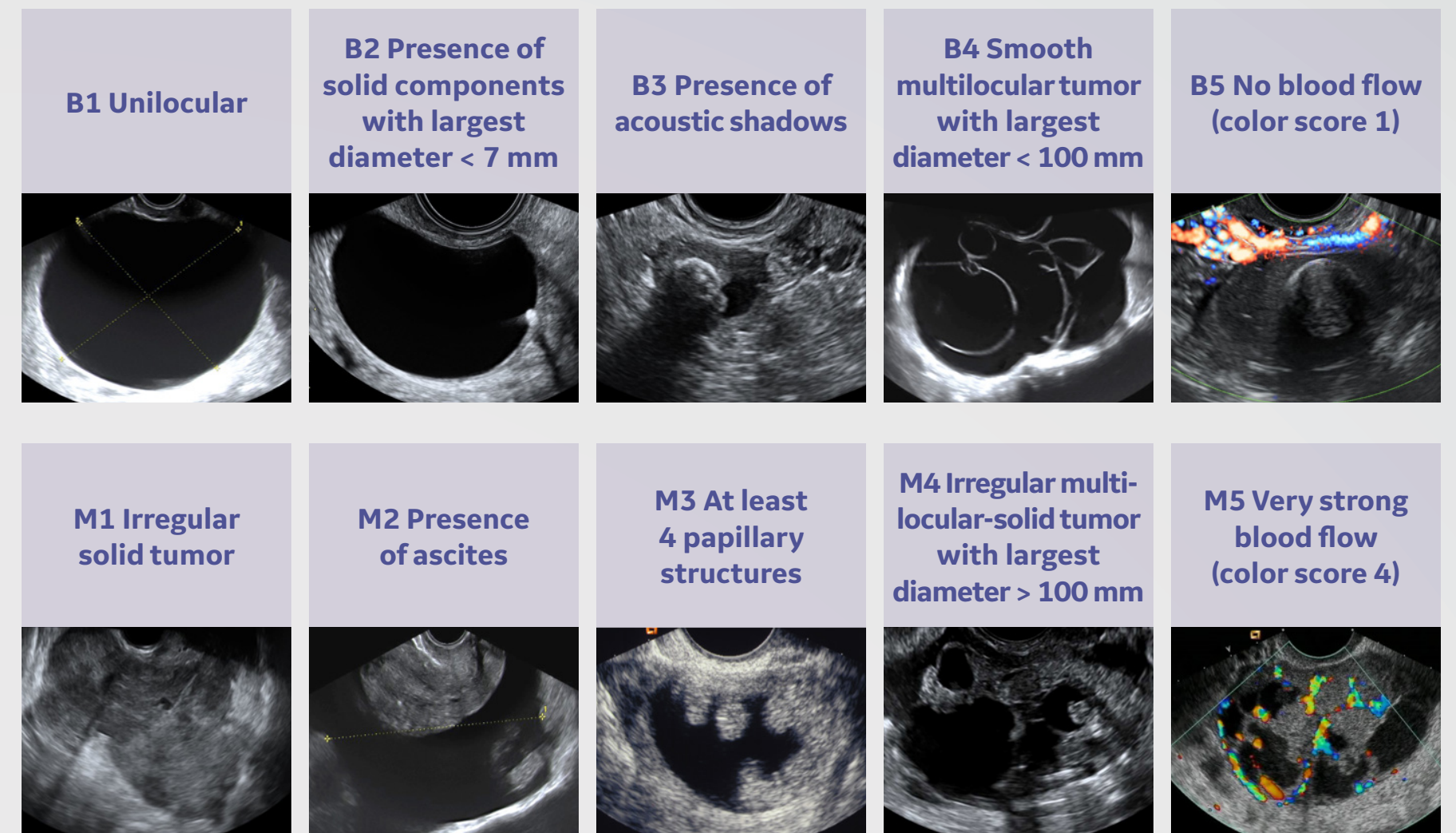
The Simple Rules consist of five features typical for benign tumors (B-features) and five features typical for malignant tumors (M-features).

Tumors are classified as Benign, Malignant or Inconclusive:

- Benign: Only B-features apply
- Malignant: Only M-features apply
- Inconclusive: No features apply, or both B- and M-features apply



Timmerman D, Van Calster B, et al. Am J Obstet Gynecol 2016;214:424-437.

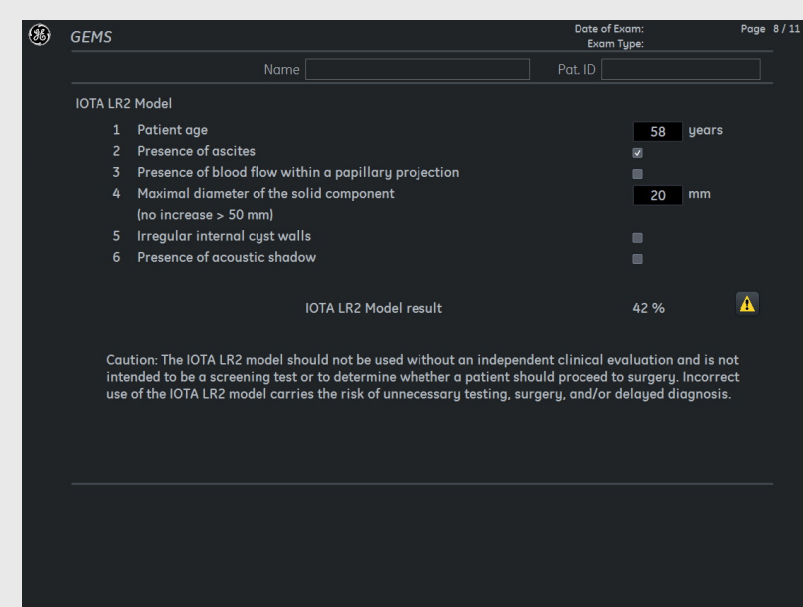

### LR2 RISK MODEL

#### Estimates probability of malignancy

LR2 uses six predictors (one clinical, plus five ultrasound):

- Age
- Maximal diameter of the largest solid component
- Irregular internal cyst walls
- Presence of papillary projections with detectable flow acoustic shadows
- Ascites



Timmerman D, et al. J Clin Oncol 2005;23:8794-801.

The algorithm produces a % of probability.

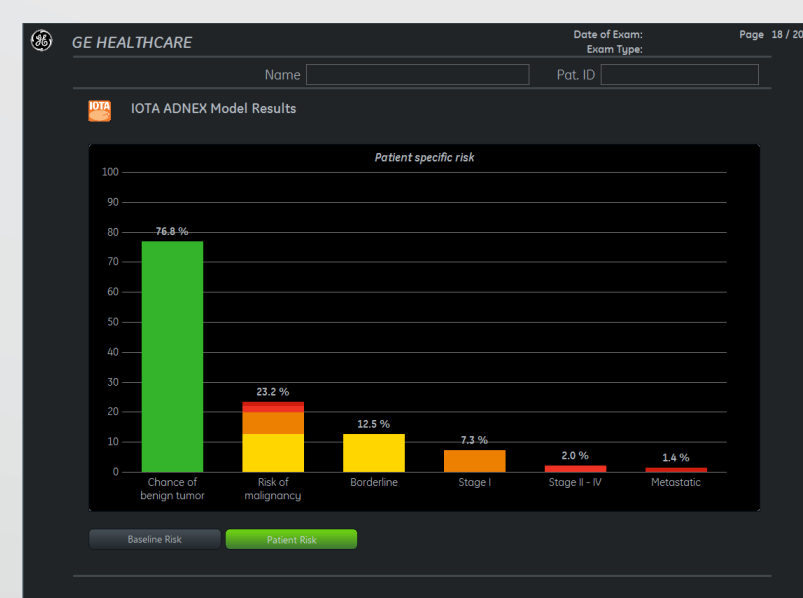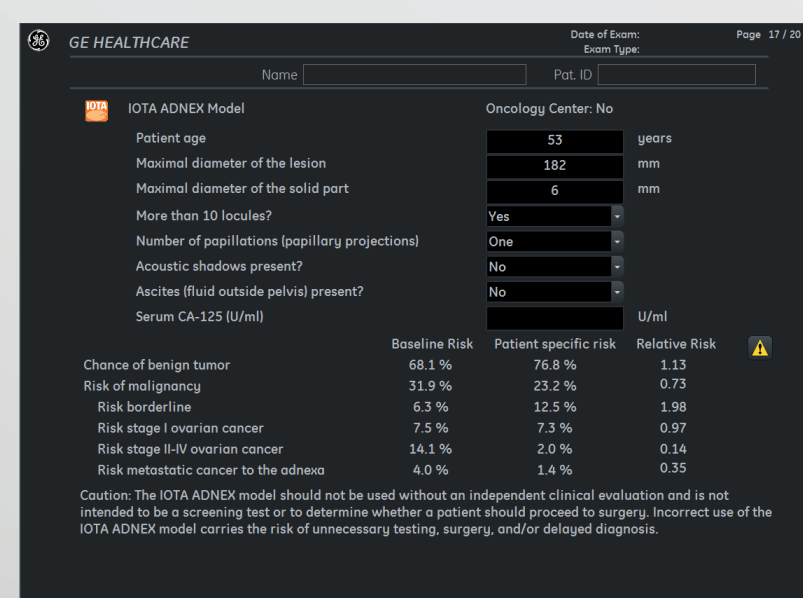### ADNEX RISK MODEL

#### Estimates probability a tumor is benign, borderline, stage 1 cancer, stage II-IV cancer or secondary metastatic cancer

The ADNEX model uses nine predictors (three clinical, six ultrasound):

- Age
- Serum CA-125 level
- Type of center
- Maximal diameter of lesion
- Proportion of solid tissue
- > 10 cyst locules
- # of papillary projections
- Acoustic shadows
- Ascites

The algorithm produces a % for various tumor types.



Van Calster B, et al. BMJ 2014;349:g5920.

### IOTA TABLE OF LESIONS

Terms and definitions from the International Ovarian Tumor Analysis (IOTA) group

- Unilocular cyst**
  - 1 A unilocular cyst without septa and without solid parts or papillary structures.
  - 2 If a cyst has only incomplete septa and no real septa, it is recorded as unilocular. An incomplete septum as seen in hydrosalpinges is defined as a thin strand of tissue running across the cyst cavity from one internal surface to the contralateral side, but which is not complete in some scanning planes.
  - 3 If there is irregular internal cyst wall without a solid papillary projection, then the cyst is also unilocular by definition. The height of excrescences should be less than 3 mm.
  - 4 The hyperreflective and avascular area ("white ball") in the center of dermoid cyst should not be classified as a solid papillary projection.
  - 5 Similarly, "sludge" on the internal walls is not regarded as a papillary projection.
- Unilocular-solid cyst**
  - A unilocular cyst with a measurable solid component or at least one papillary structure. This category may include pyo- or hydrosalpinges with the so-called "beads-on-a-string" or "cogwheel" appearance if their height is greater than or equal to 3 mm. If the solid components comprise 80% or more of the tumor than the mass is called a solid tumor.
- Multilocular cyst**
  - A cyst with at least one septum but no measurable solid components or papillary projections. A septum is not classified as a solid component and is defined as a thin echogenic strand of tissue running across the cyst cavity from one internal surface to the contralateral side.
- Multilocular-solid cyst**
  - A multilocular cyst with a measurable solid component or at least one papillary projection.
- Solid tumor**
  - A tumor where the solid components comprise 80% or more of the tumor when assessed in a two-dimensional section. A solid tumor may contain papillary projections protruding into the small cysts of the solid tumor.
- Internal cyst wall**
  - The internal cyst wall is described as being "smooth" or "irregular". If there is a solid papillary projection, then the wall is irregular by definition. In cases of "sludge" (as seen in endometriotic cysts), the internal walls are also called "irregular".
- Solid papillary projection**
  - Solid papillary projections are defined as any solid projections protruding into the cyst cavity from the cyst wall with a height greater than or equal to 3 mm. The hyperechogenic avascular area of a dermoid cyst or sludge on the internal walls are not regarded as a papillary projection. Solid papillary projections are described as being "smooth" or "irregular" (e.g. calliflower-like).
- Cystic contents**
  - The dominant feature of the cystic contents is described as:
    - 1 anechoic (black)
    - 2 low-level echogenic (i.e. homogeneous low-level echogenic as seen in mucinous tumors)
    - 3 "ground glass" appearance (homogeneously dispersed echogenic cystic contents, as often seen in endometriotic cysts)
    - 4 hemorrhagic (with internal thread-like structures, representing strands)
    - 5 or mixed (as often seen in teratomas).
- Subjective assessment of blood flow**
  - 1 Color score of 1 is given when no blood flow within the septa, cyst walls, or solid tumor areas.
  - 2 Color score of 2 is given when only minimal flow can be detected.
  - 3 Color score of 3 is given when moderate flow is present.
  - 4 Color score of 4 is given when the adnexal mass appears highly vascular with marked blood flow.
- Acoustic shadows**
  - The presence of acoustic shadows, defined as loss of acoustic echo behind a sound-absorbing structure, is noted.

Ultrasound Obstet Gynecol 2000;16:500-505.

© 2019 General Electric Company – All rights reserved.

GE Healthcare reserves the right to make changes in specifications and features shown herein, or discontinue the product described at any time without notice or obligation. Contact your GE Healthcare representative for the most current information. GE, the GE Monogram, and Voluson are trademarks of General Electric Company, GE Healthcare, a division of General Electric Company. GE Medical Systems, Inc., doing business as GE Healthcare.

August 2019  
JB69323XX