

The Pelvic Pain Patient

EASY 5-STEP ULTRASOUND EVALUATION

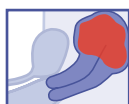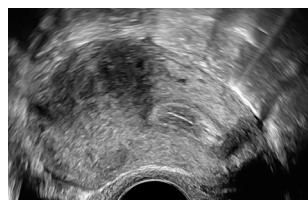


Gernot Hudelist, MD, PD, MSc

Clinical Lecturer | Head, Certified Tertiary Referral Center for Endometriosis,
Hospital St. John of God, Vienna
Woman and Health Private Clinic, Vienna, Austria

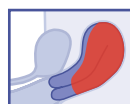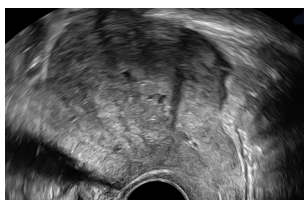
1. UTERUS

Adenomyosis – Nodular



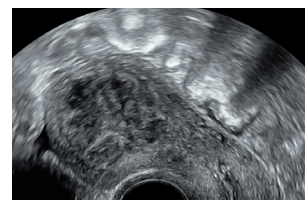
Asymmetry,
shadowing,
irregular perfusion

Adenomyosis – Diffuse



Ill-defined with
diffuse perfusion

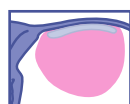
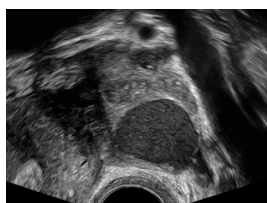
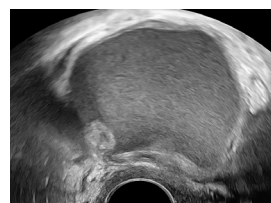
Fibroid



Round-shaped
with perfusion

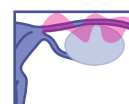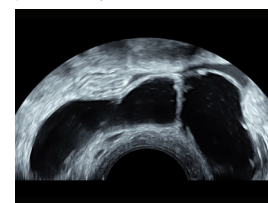
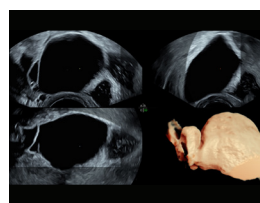
2. ADNEXAL REGION

Endometrioma



Ground glass
appearance

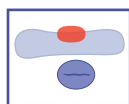
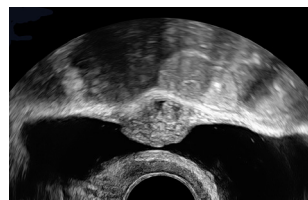
Hydrosalpinx



Irregular septae
characterized by
a "cogwheel sign"

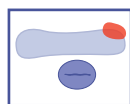
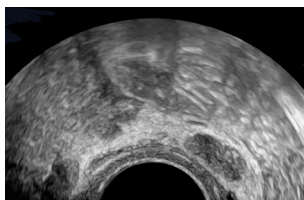
3. URINARY BLADDER

Central Bladder – Deep Endometriosis



Transverse Plane

Lateral Bladder – Deep Endometriosis

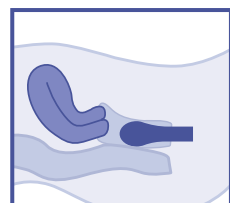


Transverse Plane

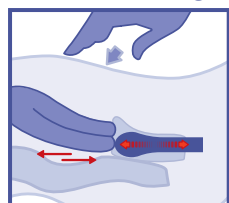
- Iso/hyperechoic
- Nodular
- Ill-defined border
- Disruption of muscular layer

4. POSTERIOR COMPARTMENT SLIDING SIGN – POD OBLITERATION

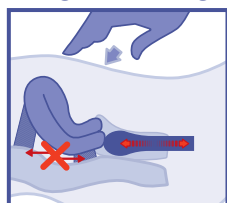Neutral



Positive Sliding



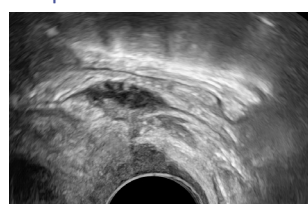
Negative Sliding



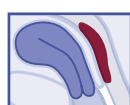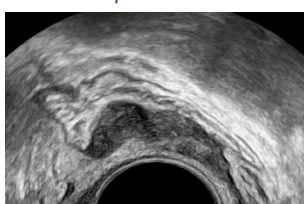
- Bimanual exam (optional)
- Sliding uterus against middle rectum

5. POSTERIOR COMPARTMENT – RECTOVAGINAL DEEP ENDOMETRIOSIS

Deep Endometriosis of Rectum and Vagina



Deep Rectal Endometriosis



- Anechoic nodule
- Lack of perfusion