

Fetal brain gyration

- Dr Jean-Philippe Bault, Lumière Platform Necker, CPDP Poissy St-Germain, Les Mureaux
- Grégoire Potelle, Voluson France

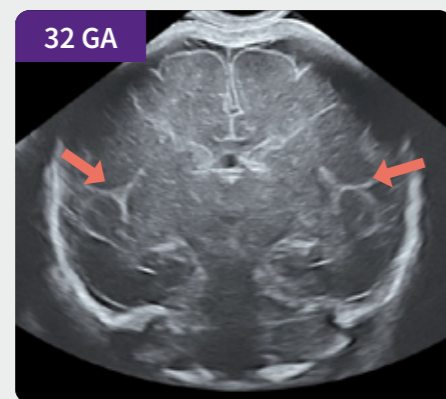
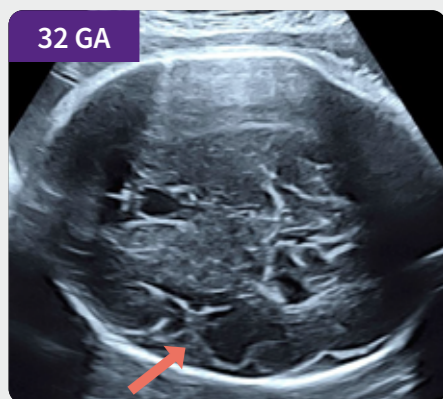
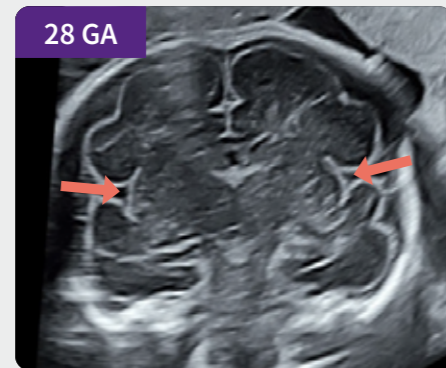
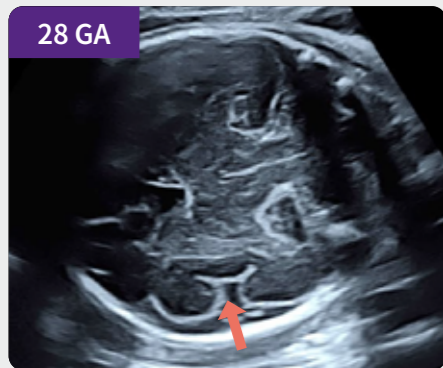
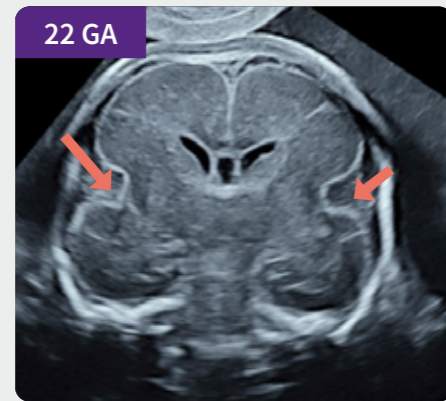
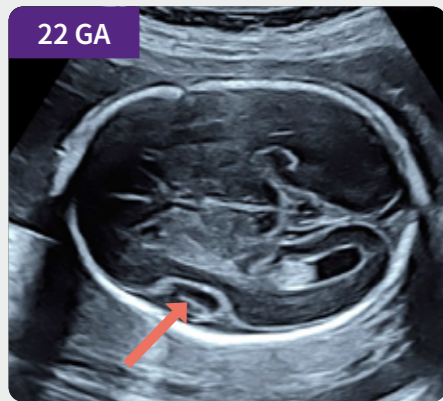
Discover more on Voluson Club

Sylvian fissure

Axial view

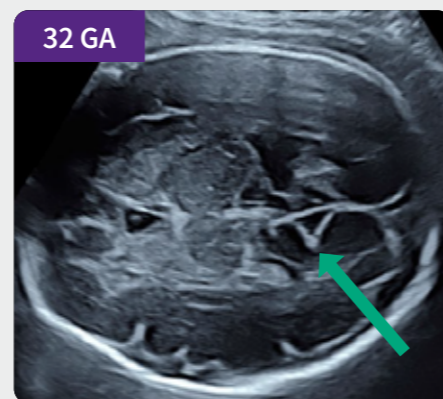
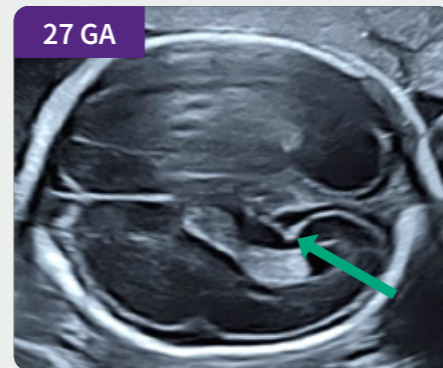
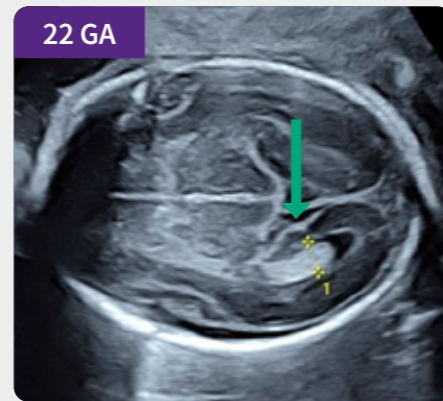
Coronal view



Primary marker of gyration
Appreciable symmetry in coronal view

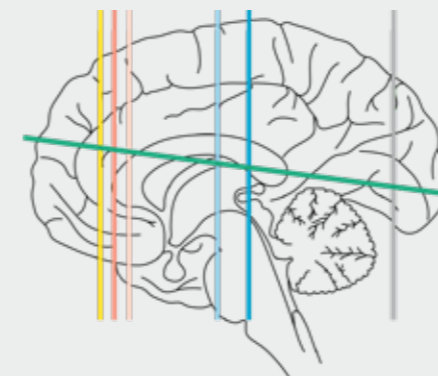
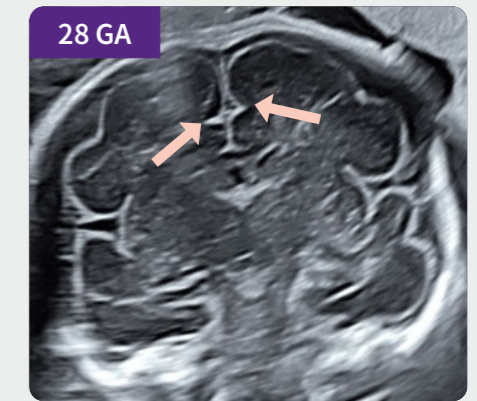
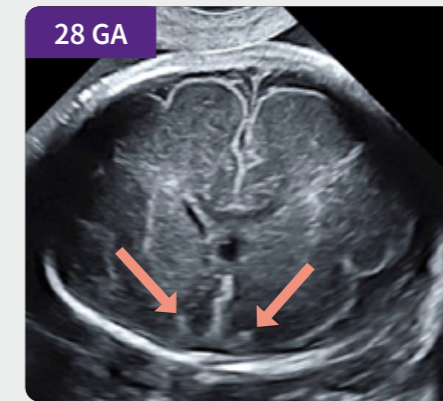
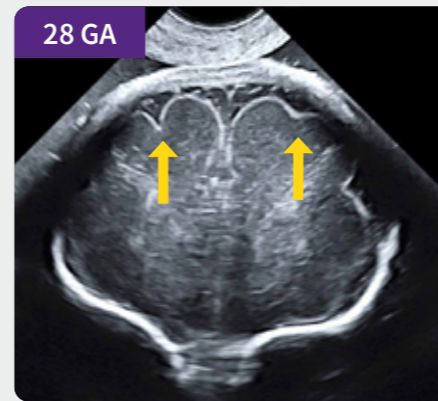
Internal occipital sulcus

Axial view



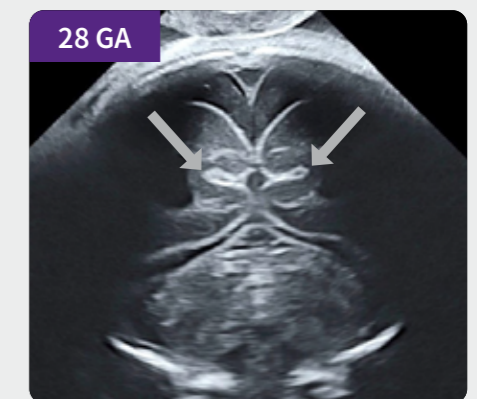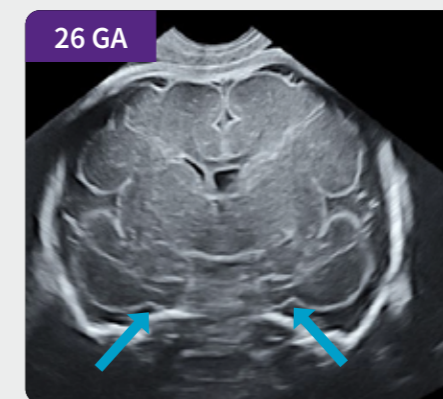
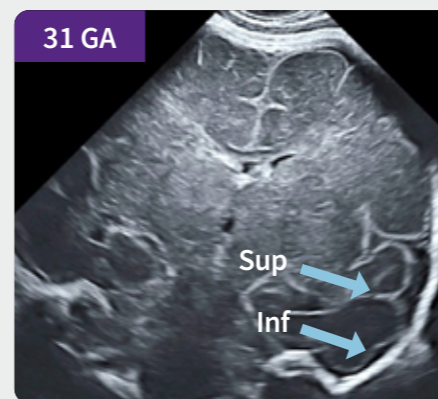
Axial view – Mark for measuring the atrial diameter

Sulci visible in the coronal plane



- Superior frontal sulci
- Olfactory sulci
- Cingulate sulci
- Temporal sulci
- Collateral sulci
- Calcarine fissure
- Internal occipital sulcus

	GA ✓	21 22	24	26	28	31
Internal Occipital S.	✓					
Calcarine F.			✓			
Cingulate S.				✓		
Collateral S.				✓		
Sup. Frontal S.					✓	
Olfact. S.					✓	
Sup.Temp. S.					✓	
Inf. Temp. S						✓



Imaging planes and anatomical illustrations are color-coded for clarity.
The accompanying table provides standardized terminology for structure visualization.